

Prosthodontics

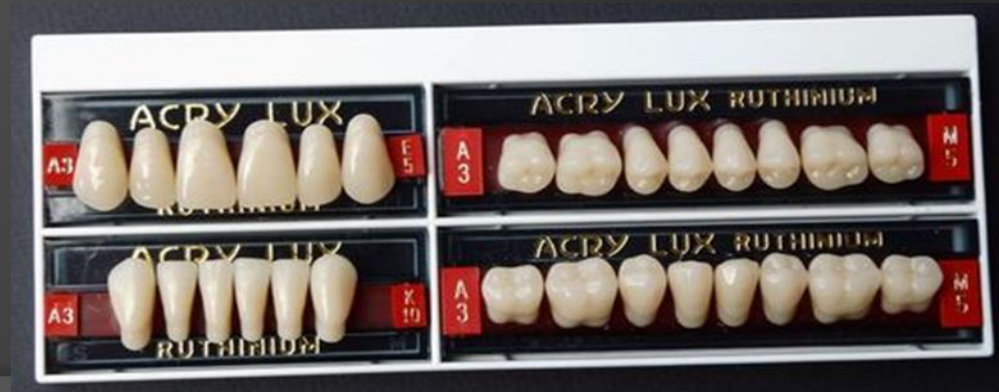Selection of artificial teeth

Prof. Dr. Mohammed Alkhafagy

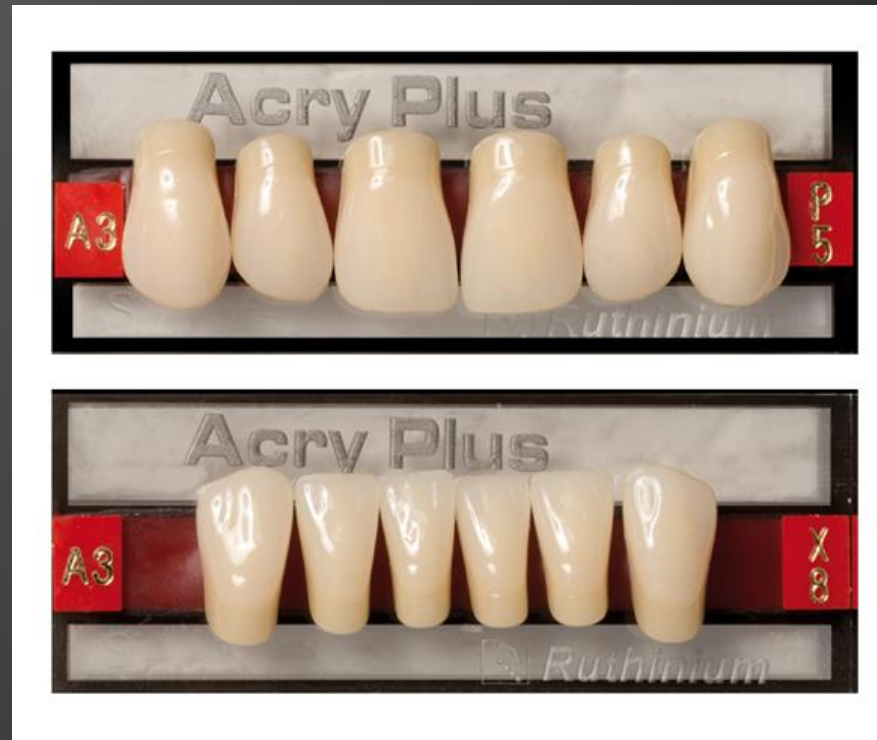Selection of artificial teeth



Selection of anterior teeth Selection of posterior teeth



Selection of anterior teeth



Selection of anterior teeth:

Anterior teeth are primarily selected to satisfy

esthetic

Requirements.

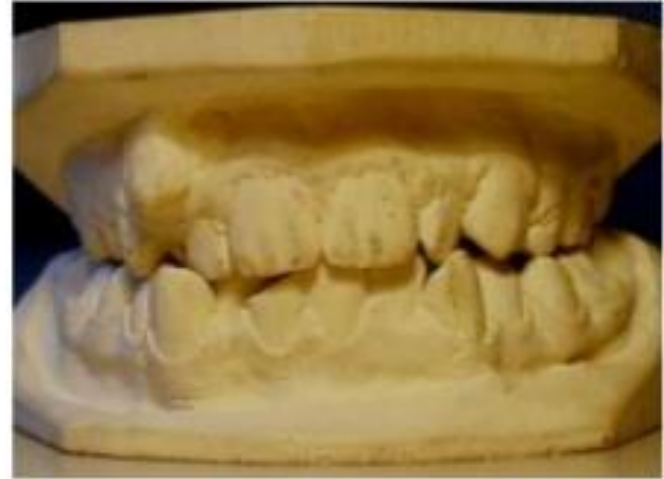
Record size, form and shade of teeth could be

*obtained from **pre-extraction records***

which include:

Pre – Extraction Records

- Facial Photographs
- Diagnostic Casts
- Radiographs
- Teeth of Close Relatives
- Extracted teeth.



Factors to be considered when pre-extraction records are **not available:**

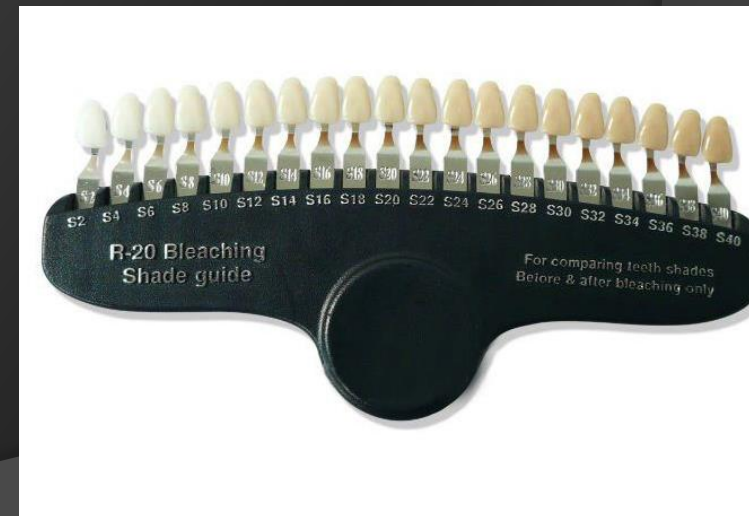
a- Shade (color).

b- Size.

c-Form.

Shade

- ❖ Shade mean degree of darkness of the color.
- ❖ There are two basic shades, **yellow** and **gray** are the basic shades and other shades vary in between.



The factors effect on shade selection are:

1-Age.

2-Sex.

3-Complexion.

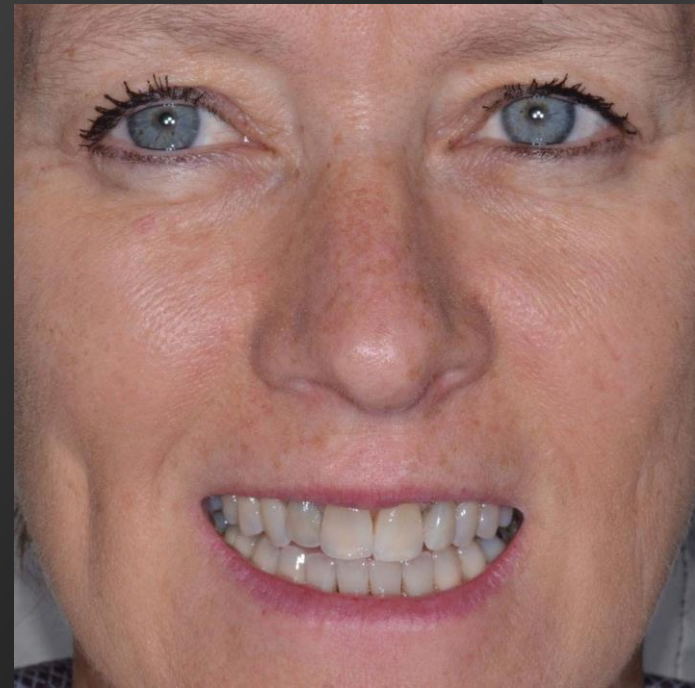
4-Patient preference.

1- Age:

The younger patient, the lighter color is preferred. The color of natural teeth darken with age because of :

- deposition of secondary dentin,
- wearing away of enamel,
- external staining from oral fluids, foods or tobacco.

Shade



2- Sex:

The sex may effect color, it seems that females given brighter teeth than males.



3- Complexion:

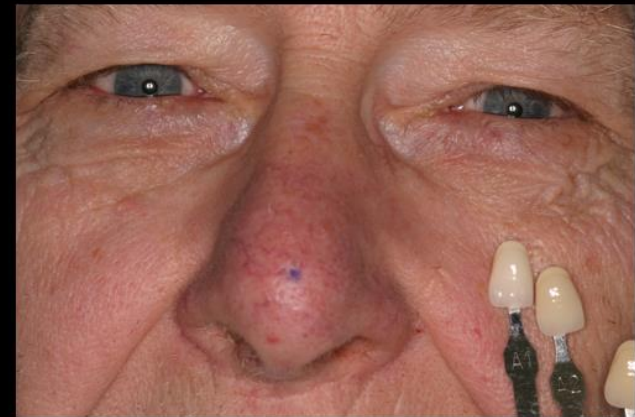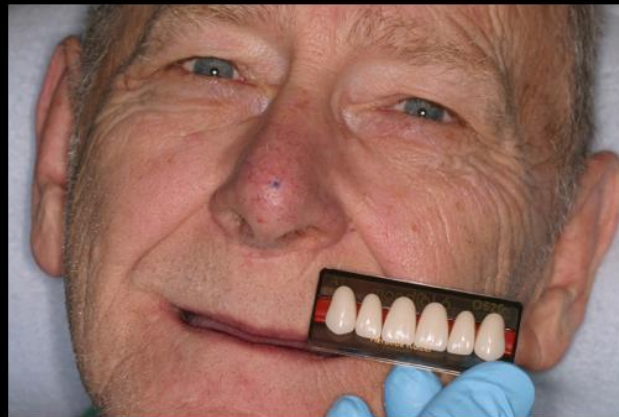The color of the face should **harmonize** the color of teeth.

Lighter teeth are **suitable** for lighter skin, while darker teeth are **suitable** for darker skin.



4-Patient preference (method of pair comparison):

Show the patient a complete shade guide and select the two tabs that are lightest and darkest, hold them against the patient lip and ask them to point to the one that they prefer.



Size:

To select size of anterior teeth we have to consider the following:

1-Length.

2-Width.

3-Method of pair comparison.

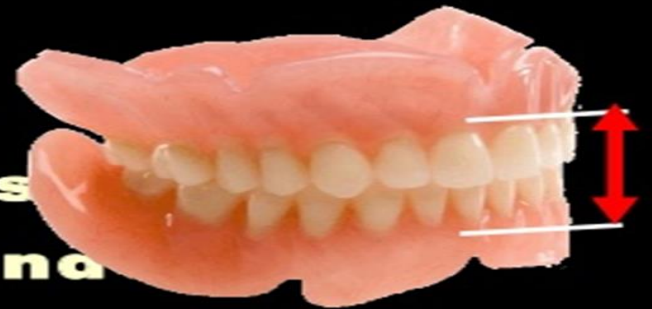1- Length: The length of upper anterior teeth is controlled by:

Size

- Inter-ridge distance.

Inter-alveolar distance inter-ridge distance

- **The vertical distance between specified positions on the maxillary and mandibular alveolar ridges at the occlusal vertical dimension.**



1- Length: The length of **upper anterior** teeth is controlled by:

Size

- **Length of upper lip.**

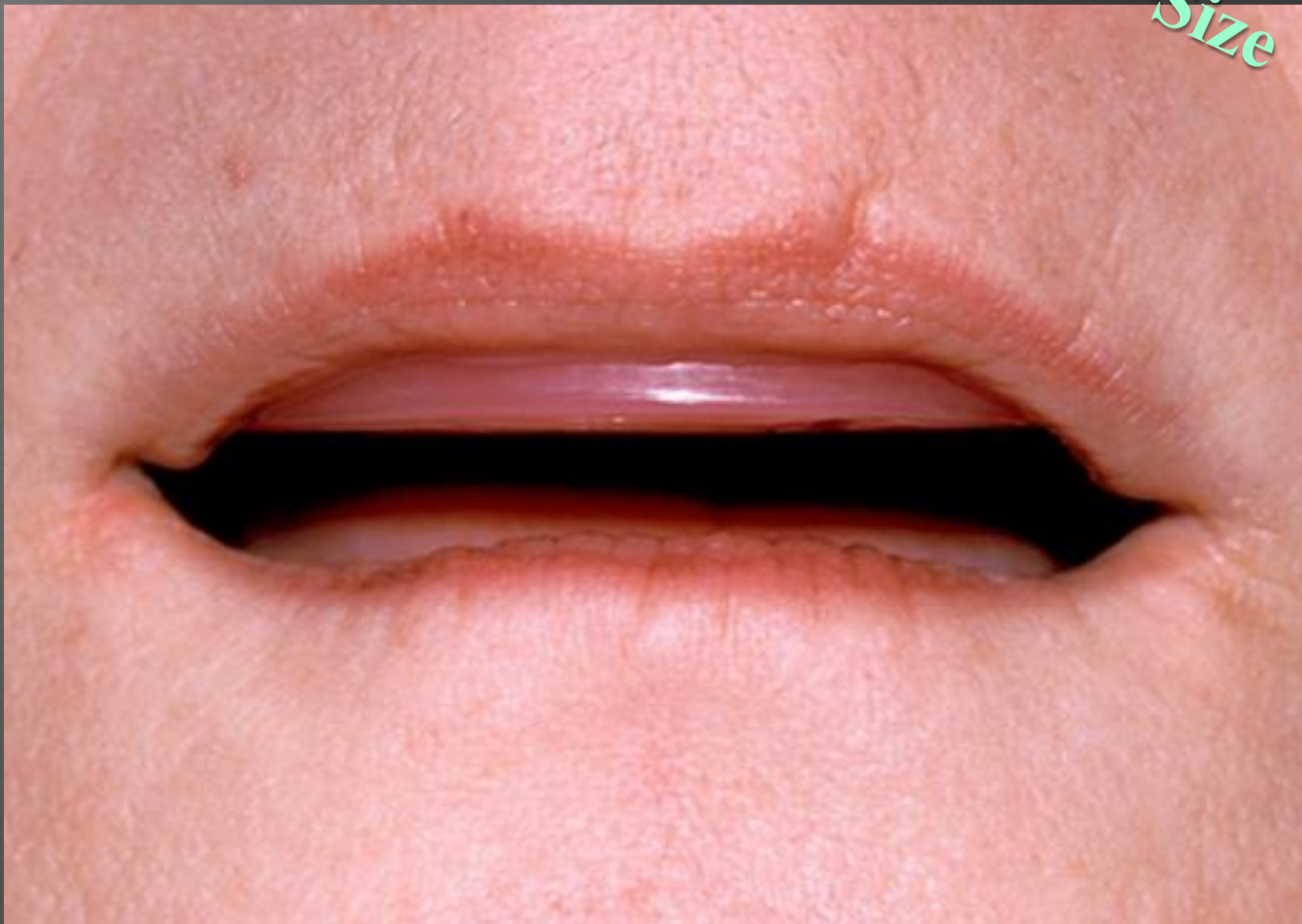a- **In short lip** more than 2mm seen from upper central incisor.

b- **In medium lip** 1-1.5 mm seen from upper central incisor.

c- **In long lip** nothing can be seen from upper central incisor.

The length of **lower anterior** teeth should be with level of lower lip.

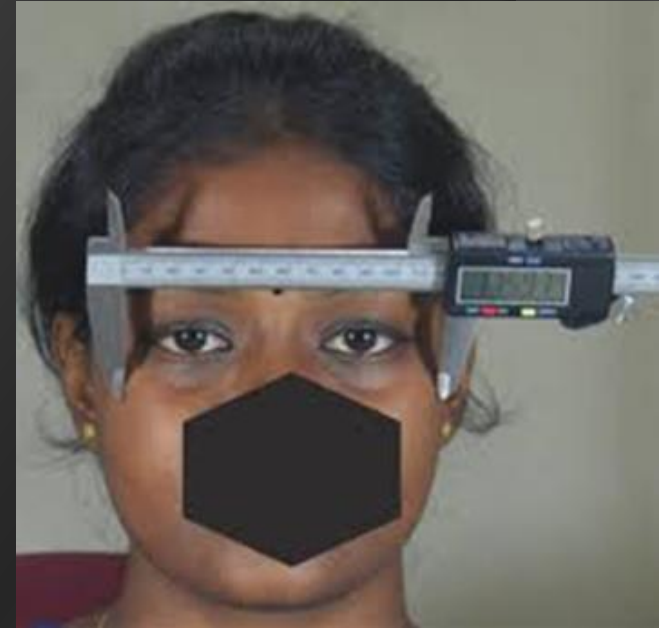Size



2- Width:

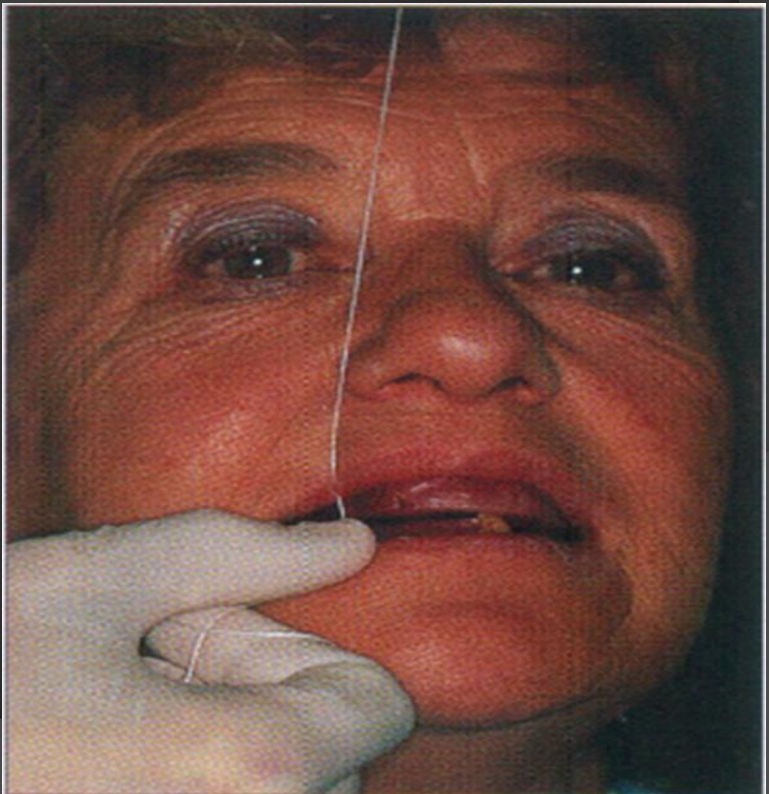
a- Measuring the width of anterior teeth

- Bizygomatic width/16 = Estimated width of maxillary central incisors
- Bizygomatic width/ 3.3 = Approximate width of 6 anterior teeth.

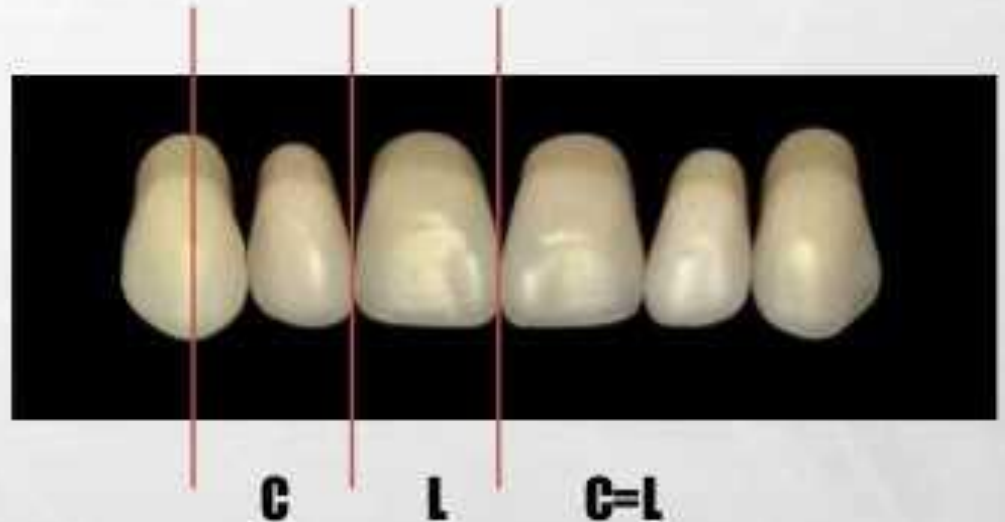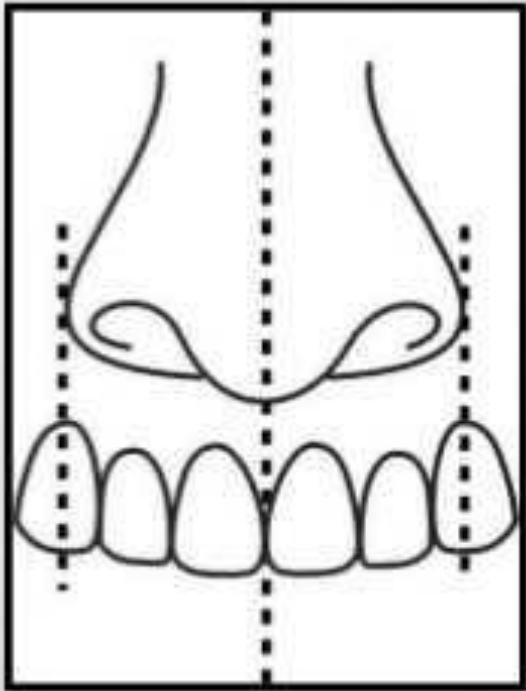


Size

b-The width from the tip of left canine to the right canine is almost equal to the width of the nose when measured in a straight line by a caliper.



WIDTH OF NOSE



Boucher and Hoffman et al.

referred to the nasal index \rightarrow width of nose
= width of anteriors from central to centre of
canine

c- Width of anterior teeth can be measured on upper occlusion rim

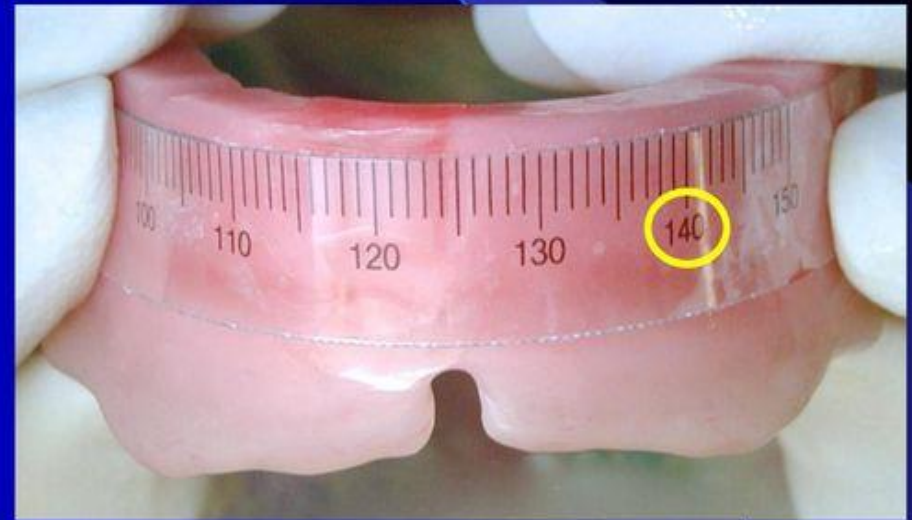
Size

depending on:

- **buccal frenum,**
- **corner of the mouth,**
- **canine eminence.**

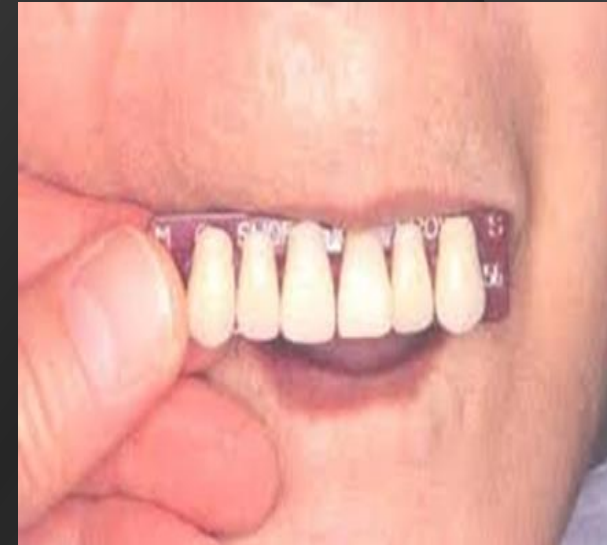Corners of the Mouth

- Measure circumference between marks with Trubyte Auto-Rule
- Size of 6 anterior teeth read off ruler (mm or by letter code A, B, etc.)



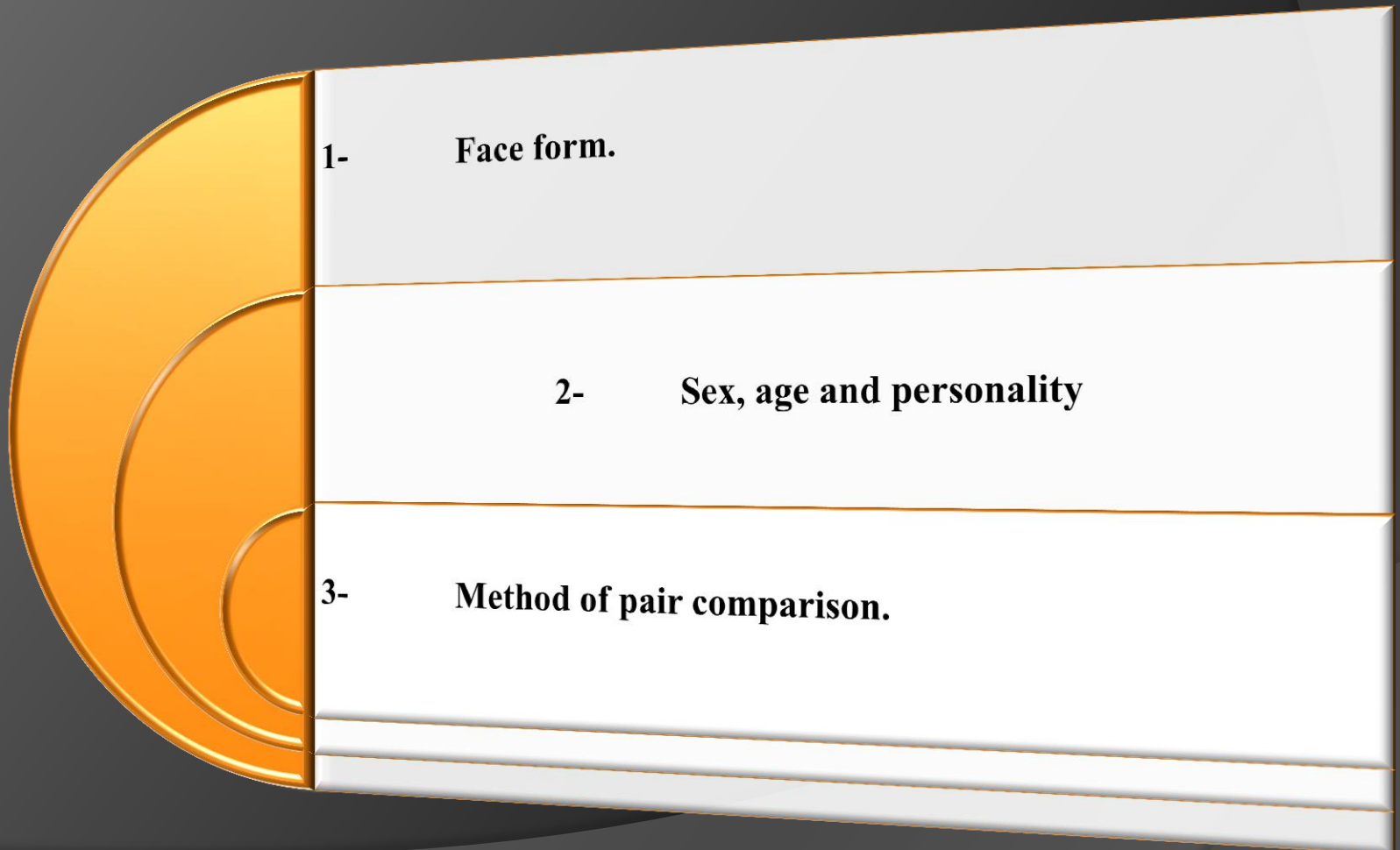
3- Method of pair comparison:

- Use the method of pair comparison to assist a patient to decide what size of tooth they prefer.
- Set two different sizes of teeth on a piece of wax rope.
- Place this under the upper lip, and find out which one the patient prefers.

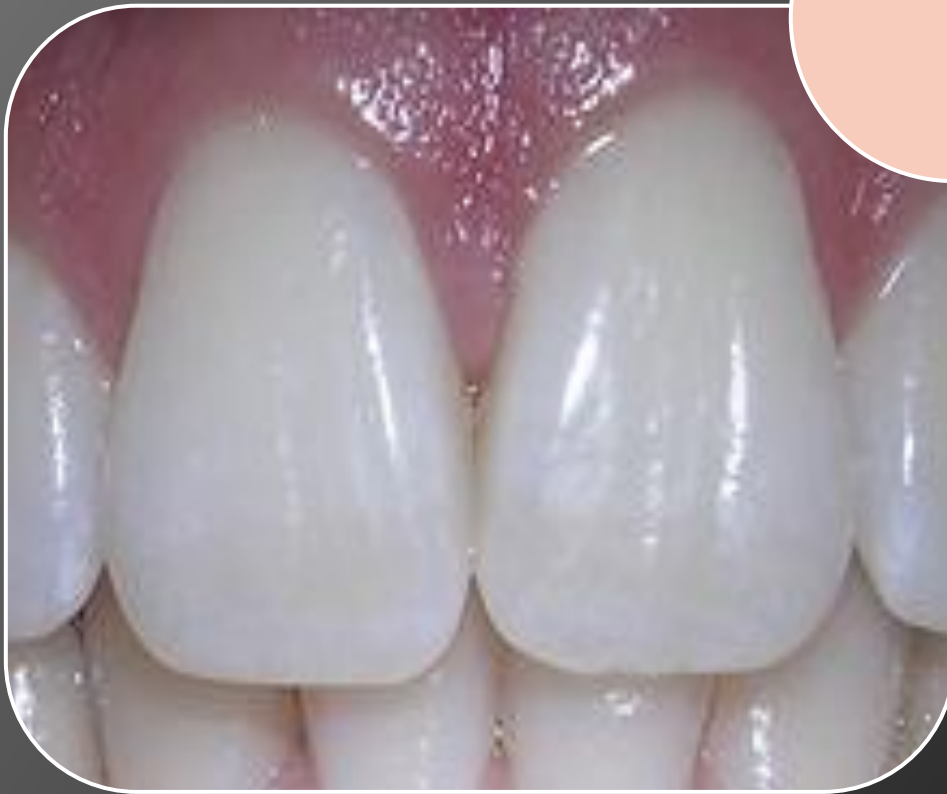

Form:

The form of anterior teeth depends on the following:



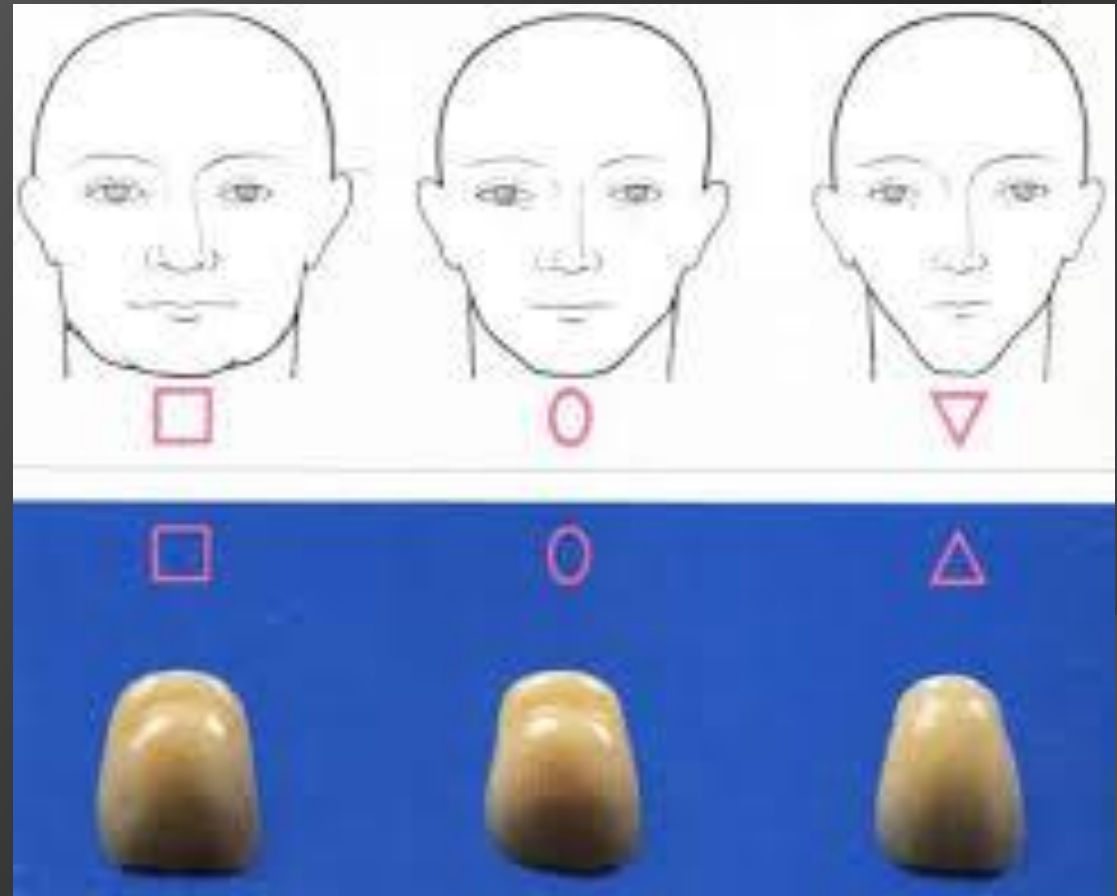
Face form



The upper central incisor form should be in harmony with patient face.

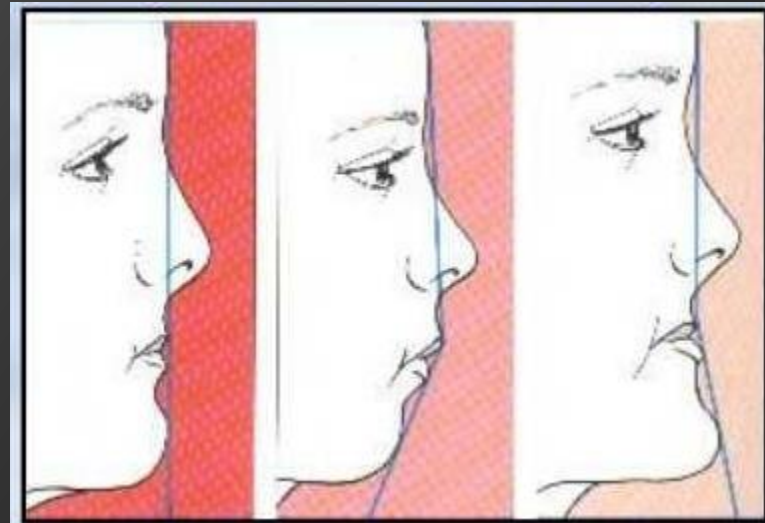
According to frontal out-line, face could be classified into:

- square,
- ovoid,
- tapering.



According to profile of the face, face can be divided into: ***straight, convex and concave.***

The labial surface of upper central incisor viewed from the mesial aspect should be in harmony with profile of the face.



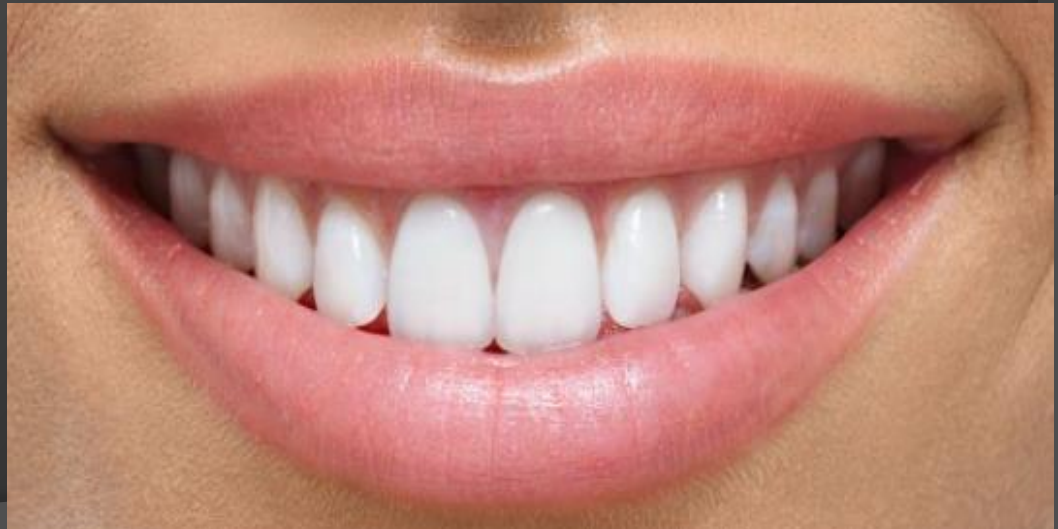2- Sex, age and personality:

- Sex:

Masculine form.

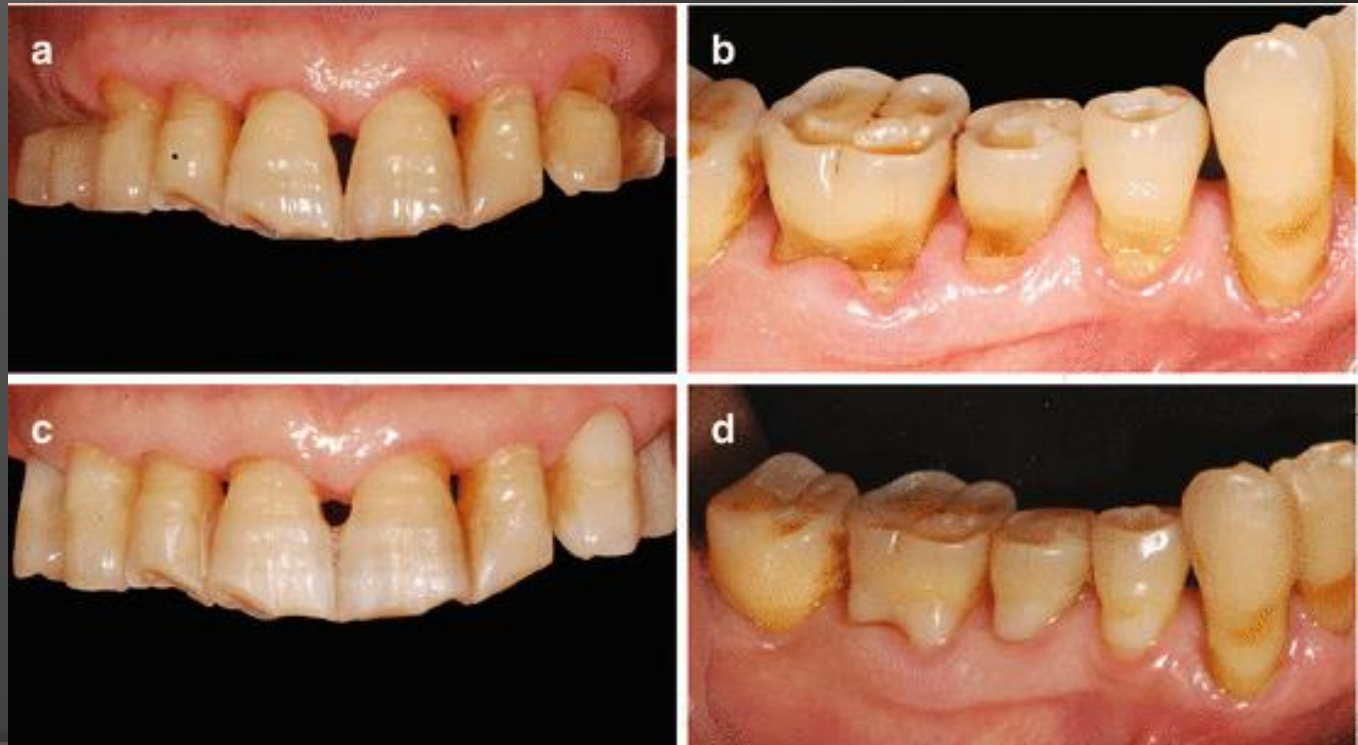


Feminine form.



- Age:

in old patients the teeth tend to have **square** form due to attrition.



- Personality:

Form

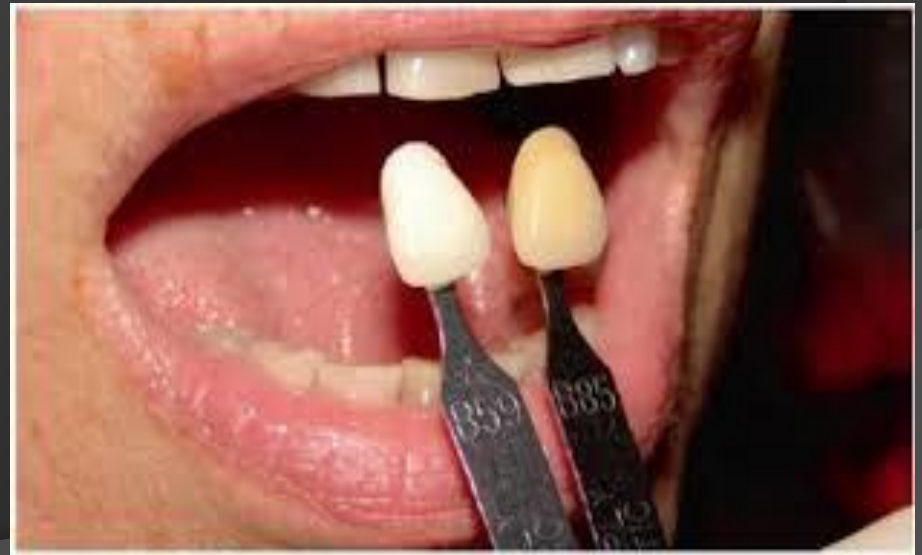It seems reasonable that a *large vigorous type* of persons have teeth of a size and form with prominent markings, different from those of a delicate appearing woman.



- Method of pair comparison:

Form

Allow the patient to select between the same size teeth on the right and left sides of a piece of wax rope, and ask the patients which they prefer.



Materials of anterior teeth ☺

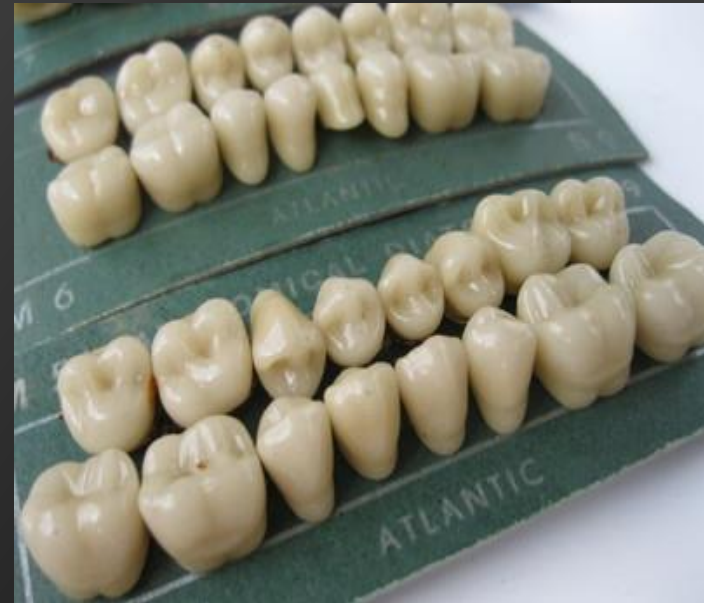```
graph LR; A[Materials of anterior teeth ☺] --- B[1- Porcelain teeth: ☺]; A --- C[2- Acrylic teeth: ☺]
```

1- Porcelain teeth: ☺

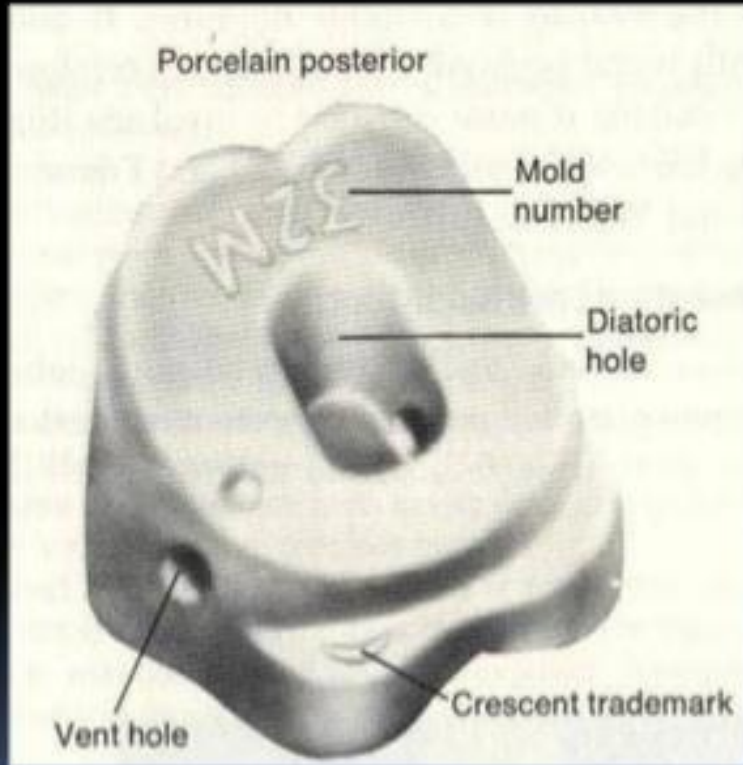
2- Acrylic teeth: ☺

1- Porcelain teeth:

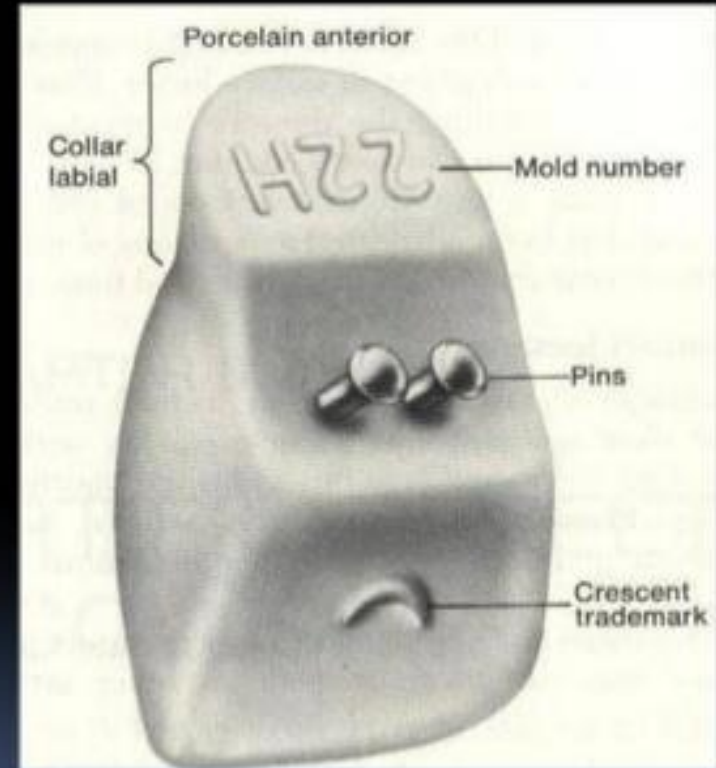
Generally porcelain teeth are preferred particularly for young person **because** they look more vital, very smooth and difficult to abrade.



Porcelain teeth



The posterior teeth are retained by acrylic resin in their diatoric holes

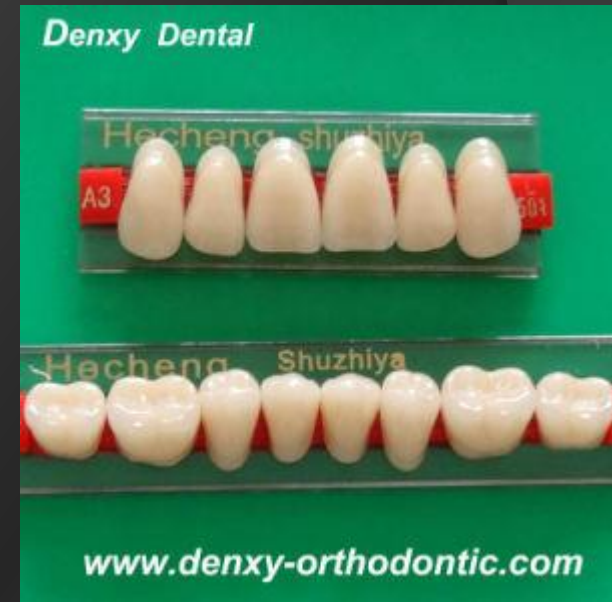

The anterior porcelain teeth are retained by acrylic resin surrounding their retention pins

2- Acrylic teeth:

Indications

- *There is insufficient inter-occlusal distance and grinding becomes necessary,*
- *In situation where there are opposing natural teeth, partial denture and gold bridge.*



Acrylic teeth

Porcelain teeth

Not brittle, but poor abrasion resistance.

Brittle, more resistance to abrasion.

Esthetic very good.

Excellent (does not stain).

Chemical bonding with denture base.

Mechanical bonding by pins or undercuts holes.

Easily ground and polish.

Difficult to grind and polish.

Transmit less forces to the mucosa.


More forces to the mucosa.

No clicking on contact.

Clicking on contact.

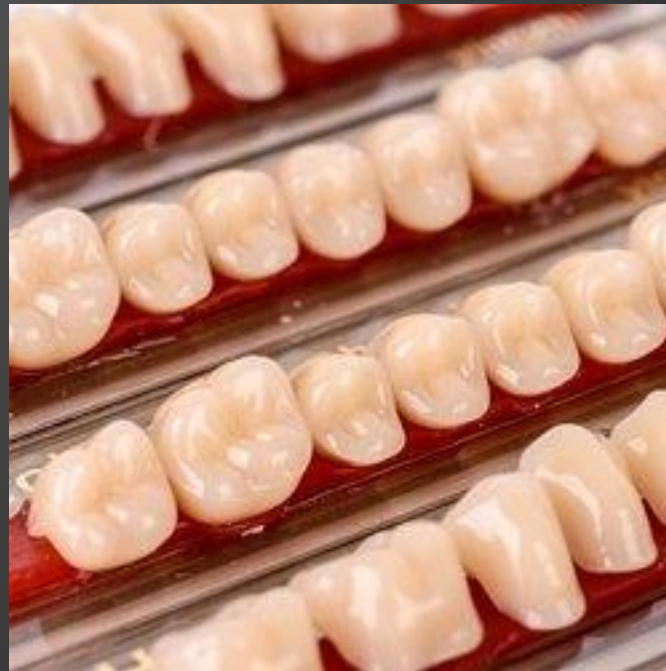Thermal expansion same as acrylic denture base.

Much more than acrylic causes stresses in acrylic denture base.

A top-down photograph of a wooden desk. On the left is a bright green mug. In the center is a white piece of paper with the words 'TAKE A BREAK' written in large, bold, black, hand-drawn capital letters. A black pen lies vertically to the left of the paper. To the right of the paper is a black smartphone. The background is a light-colored wooden surface.

TAKE A
BREAK

Selection of posterior teeth



Selection of posterior teeth:

Posterior teeth are selected for:

- ❖ **Shade**

- ❖ **Size**

- **Width (bucco-lingual width, mesio-distal width)**

- **Vertical height (occluso-gingival length)**

- ❖ **Occlusal form.**

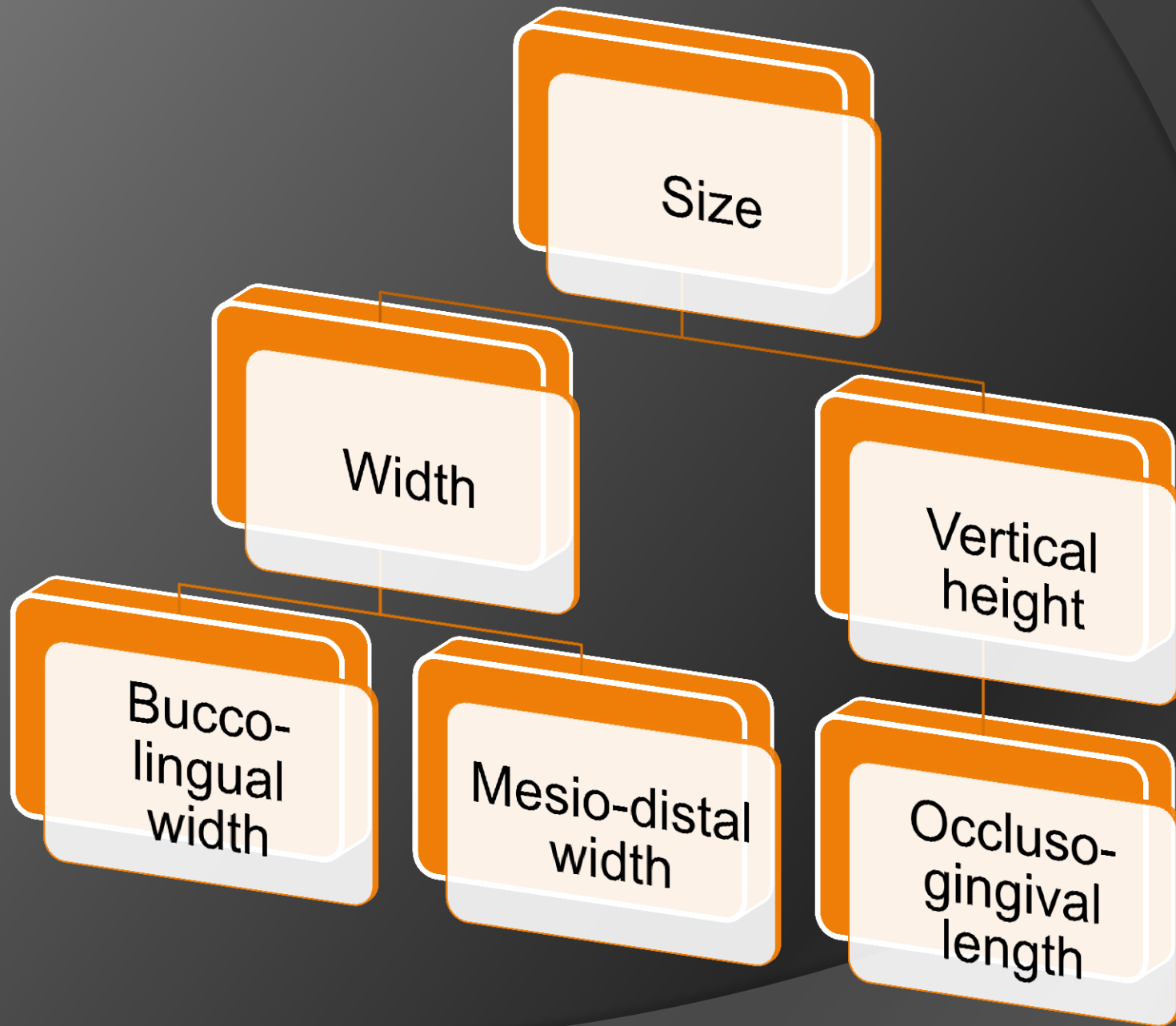
Shade:

It should harmonize with the shade of anterior teeth.

The bicuspids may be slightly lighter than the posterior teeth but not lighter than the anterior teeth.

Size

- Bucco-lingual width
- Mesio-distal width
- Vertical length of buccal surface of posterior teeth

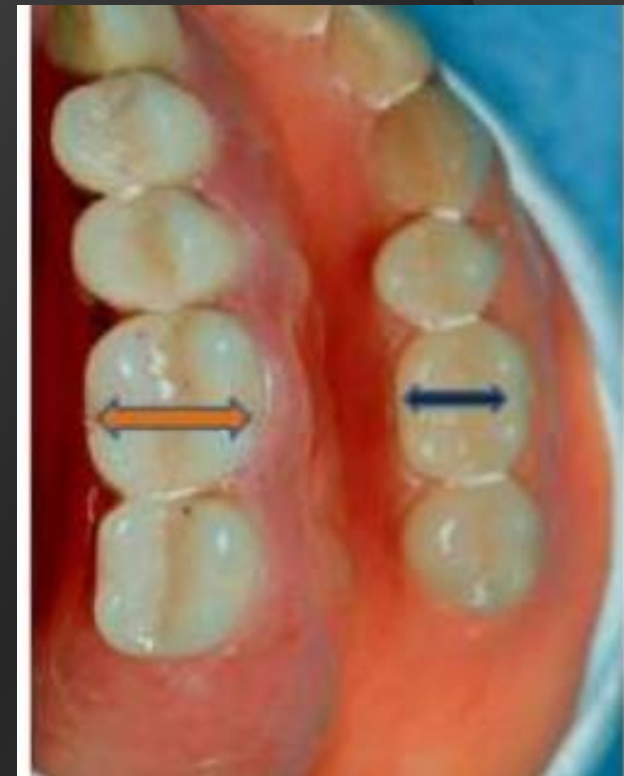

Bucco-lingual width:

size

The bucco-lingual width of posterior teeth should be slightly narrower than natural teeth *to*

- decrease occlusal surfaces which direct less stress during function to supporting tissue,
- enhance the development of the correct form of polished of the denture.

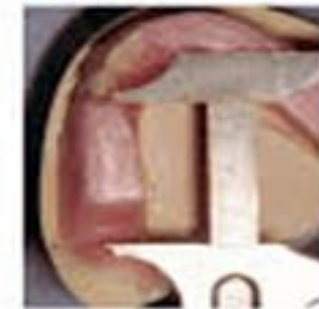

Mesio-distal width:

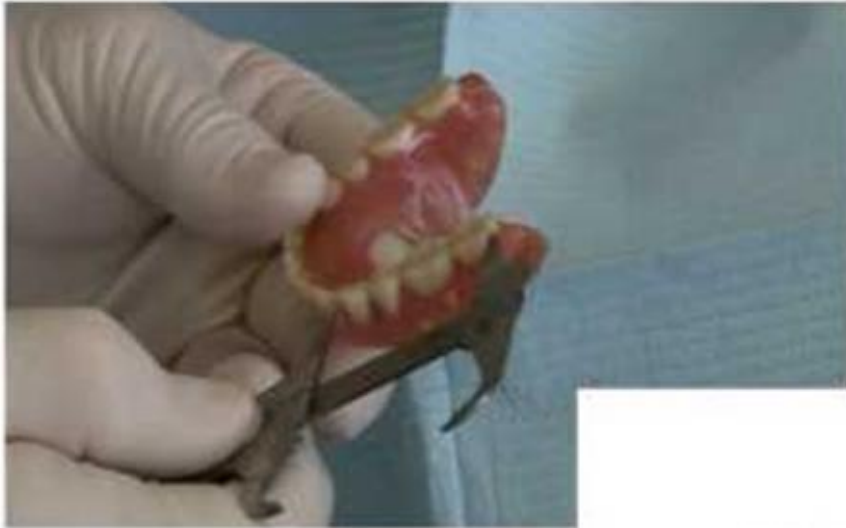size

- The mesio-distal width of posterior teeth should be equal to the distance between canine line and anterior border of maxillary tuberosity for upper teeth.
- For lower teeth should be equal to distance between canine line and anterior border of retro-molar pad area.

Determine distance from distal of canine to ascending ramus (29, 30 mm, etc.)



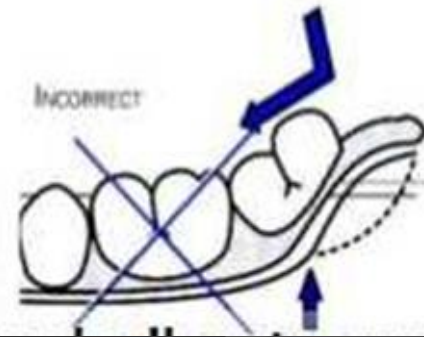
size



CORRECT



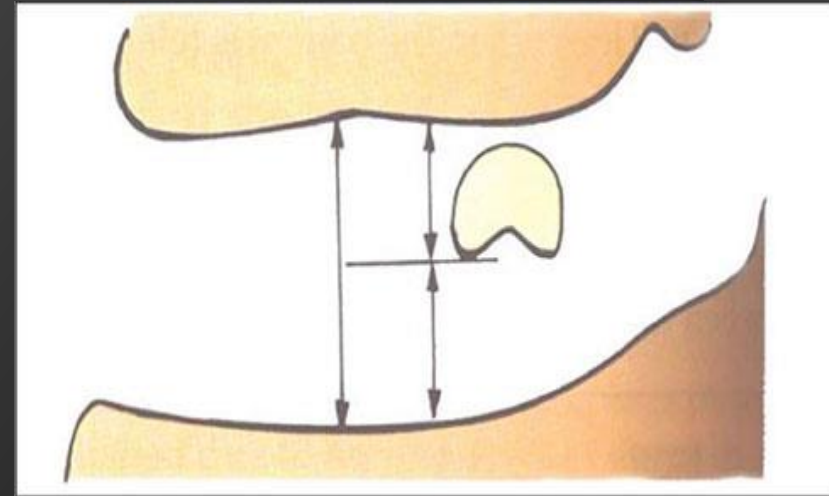
INCORRECT



occluso-gingival length

size

- It is best to select posterior teeth corresponding to the inter-arch space and to the length of anterior teeth.
- The height of posterior teeth usually divided into **long, short and medium.**
- Long posterior teeth are generally more esthetic in appearance than are shorter teeth.



Occlusal form:

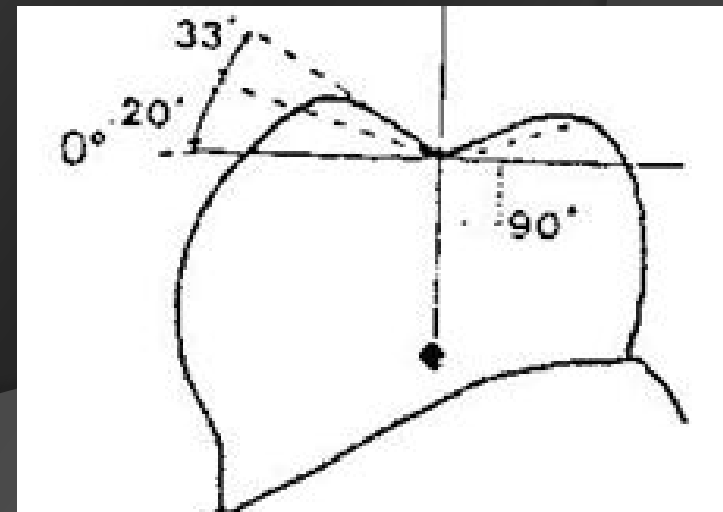
Cuspal angulation: The inclination is measured as the angle formed by the mesial slope of the mesio-buccal cusp of mandibular molar with the horizontal.

Types of teeth according to Cuspal angulation:

- *33° Teeth*

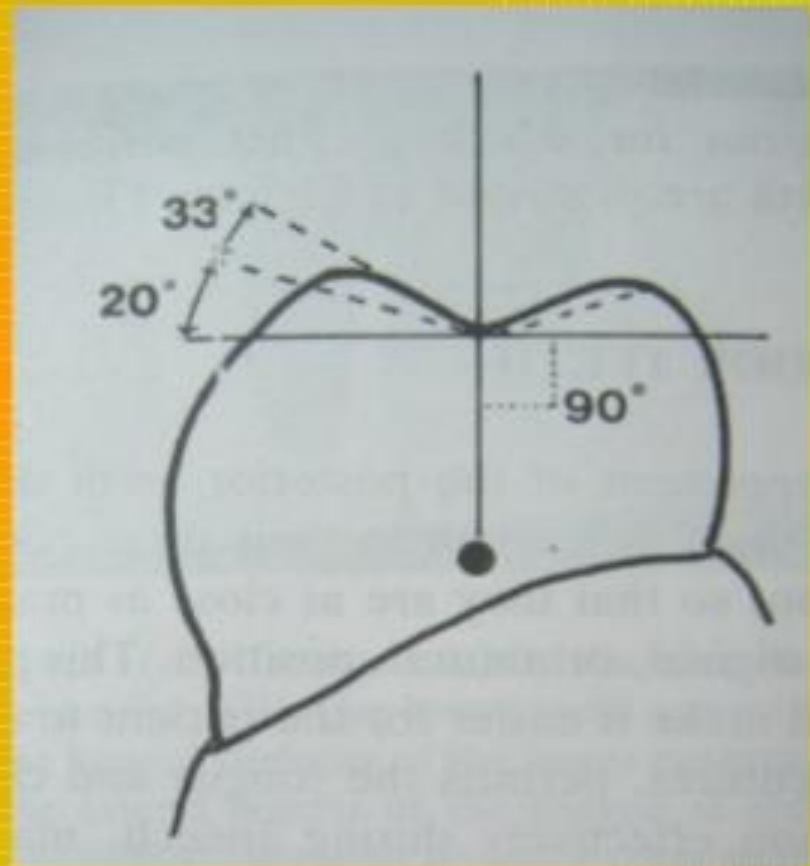
- *20° Teeth*

- *0° Teeth*



Occlusal form

- 33° bucco-lingual inclines of anatomic teeth for patients with strong, well formed ridges
- 20° bucco-lingual inclines of semi-anatomic teeth for patient with ridge contour is reduced by resorption
- 0° non-anatomic teeth for patient with flat, knife edge ridges



Occlusal form



33 degree
Anatomic



20 degree
Semi-anatomic

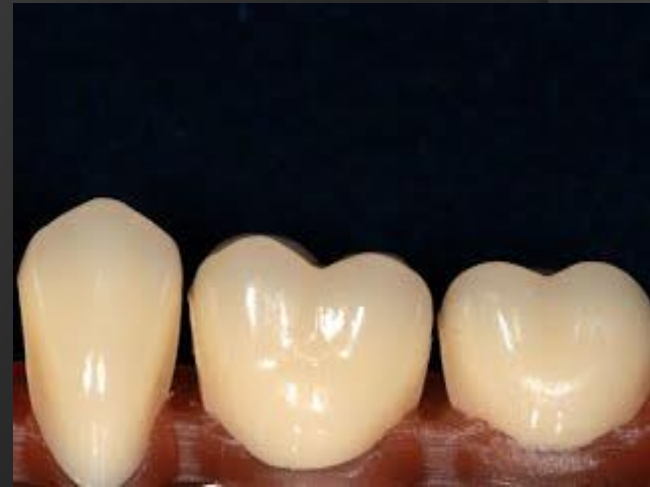

0 degree
Non-anatomic

Advantages of Anatomic Teeth

1-They are considered more efficient in cutting of food, thereby *reducing the forces that are directed at the support during masticatory movements.*

2-They can be arranged in balanced occlusion in the eccentric jaw positions.

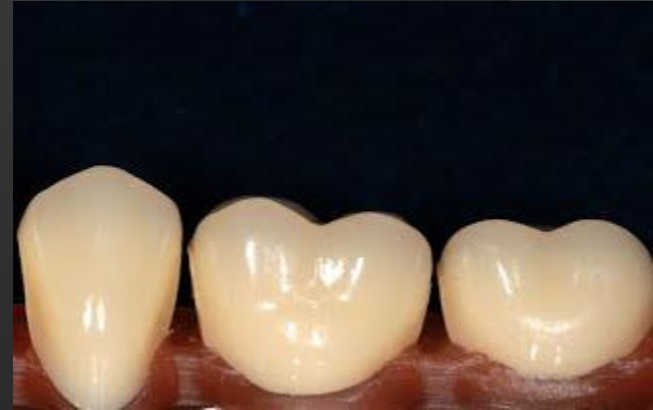

Advantages of Anatomic Teeth

3-The cusp fossa relationship between upper and lower posterior teeth form definite point for return to centric occlusion

4-They look more like natural teeth and therefore, are *acceptable esthetically*.

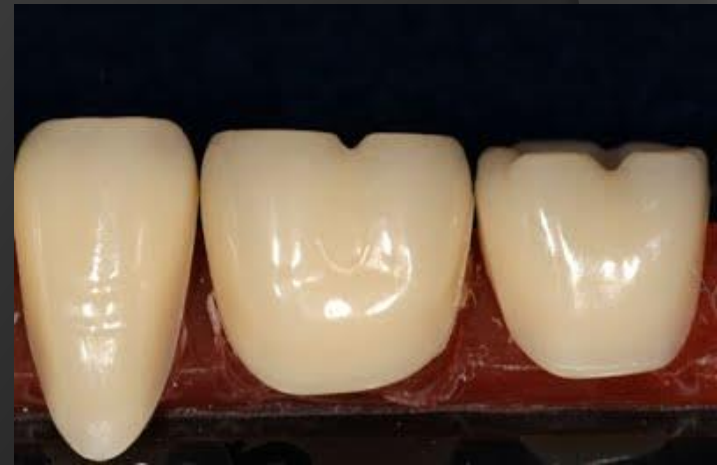5-The contours are *more like natural teeth*, therefore they will be more compatible with the surrounding oral environment.



Advantages of Monoplane Teeth

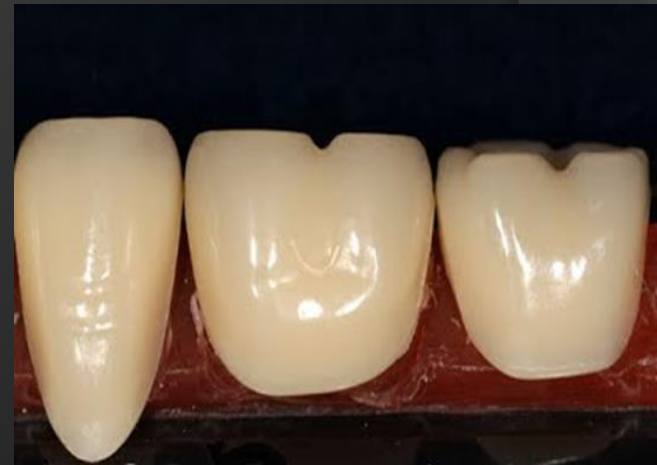1- When teeth are contacting in non-masticatory movements as in bruxism, the flat polished surfaces offer less resistance, therefore *less force is directed to the supporting tissue.*

2- Offer less resistance to lateral forces therefore, they are indicated in excessively resorbed ridges.



Advantages of Monoplane Teeth

- 3- These teeth will allow a greater range of movement, which is necessary in patients who do not provide a static jaw relation.
- 4- When neuro-muscular control is uncoordinated, the jaw relation records are not repeatable and cusp tooth cannot be balanced. Hence, monoplane teeth are indicated.
- 5- In Diabetic patients, where underlying bone is vulnerable to damage, these teeth are indicated.





Thank you